66° CONGRESSO NAZIONALE

Il ruolo della neurofisiologia nelle distonie del bambino

Nardo Nardocci
Dipartimento di Neuroscienze Pediatriche
Fondazione IRCCS Istituto Neurologico «C Besta»
Milano

Palermo
18-21 Maggio 2022

No conflict of interest related to this presentation

Experimental Brain Research (2020) 238:1685–1692
https://doi.org/10.1007/s00221-020-05863-2

REVIEW

Delineating the electrophysiological signature of dystonia

Anna Latorre[1] · Lorenzo Rocchi[1] · Kailash P. Bhatia[1]

Table 1 Electrophysiological characteristics of dystonia

Motor system	Motor system	Cerebellum	Somatosensory system
spinal cord, brainstem, cortex	basal ganglia		
Reduced inhibition:	Firing pattern:	Impaired associative motor learning:	Increased vibration-induced movement perception:
ⓘ RI (spinal cord) ⓘ BRC (brainstem) ⓘ SICI, IHI and SP (cortex)	ⓘ Low GPi and GPe discharge rate ⓘ Irregular discharges with intermittent pauses	ⓘ Abnormal EBCC	ⓘ Enhanced sensitivity of the TVR
			Increased temporal discrimination:
			ⓘ Increased STDT
Increased cortical plasticity:	Excess of synchronized activity:	Normal motor adaptation:	Reduced activity of inhibitory circuits within S1:
ⓘ PAS (spike-timing-dependent plasticity) ⓘ rTMS/tDCS and HF-RSS (homeostatic plasticity)	ⓘ Low frequency (4–10 Hz)	ⓘ Normal visual and proprioceptive sensorimotor integration tasks	ⓘ Reduced suppression of the SEP recovery cycle and reduced area of HFO
		Impaired cerebellar modulation on the motor cortex:	Abnormal somatotopic digital representation
		Absent CBI	

BRC blink recovery cycle, *CBI* cerebellar brain inhibition, *EBCC* eyeblink classic conditioning, *GPi/e* internal/external globus pallidus, *HF-RSS* high-frequency repetitive somatosensory stimulation, *HFO* high-frequency oscillations, *IHI* interhemispheric inhibition, *RI* reciprocal inhibition, *rTMS* repetitive transcranial magnetic stimulation, *S1* primary somatosensory cortex, *SEP* somatosensory-evoked potentials, *SICI* short-interval intracortical inhibition, *SP* silent period, *STDT* somatosensory temporal discrimination threshold, *tDCS* transcranial direct current stimulation, *TVR* tonic vibration reflex

Experimental Brain Research (2020) 238:1685–1692
https://doi.org/10.1007/s00221-020-05863-2

REVIEW

Delineating the electrophysiological signature of dystonia

Anna Latorre[1] · Lorenzo Rocchi[1] · Kailash P. Bhatia[1]

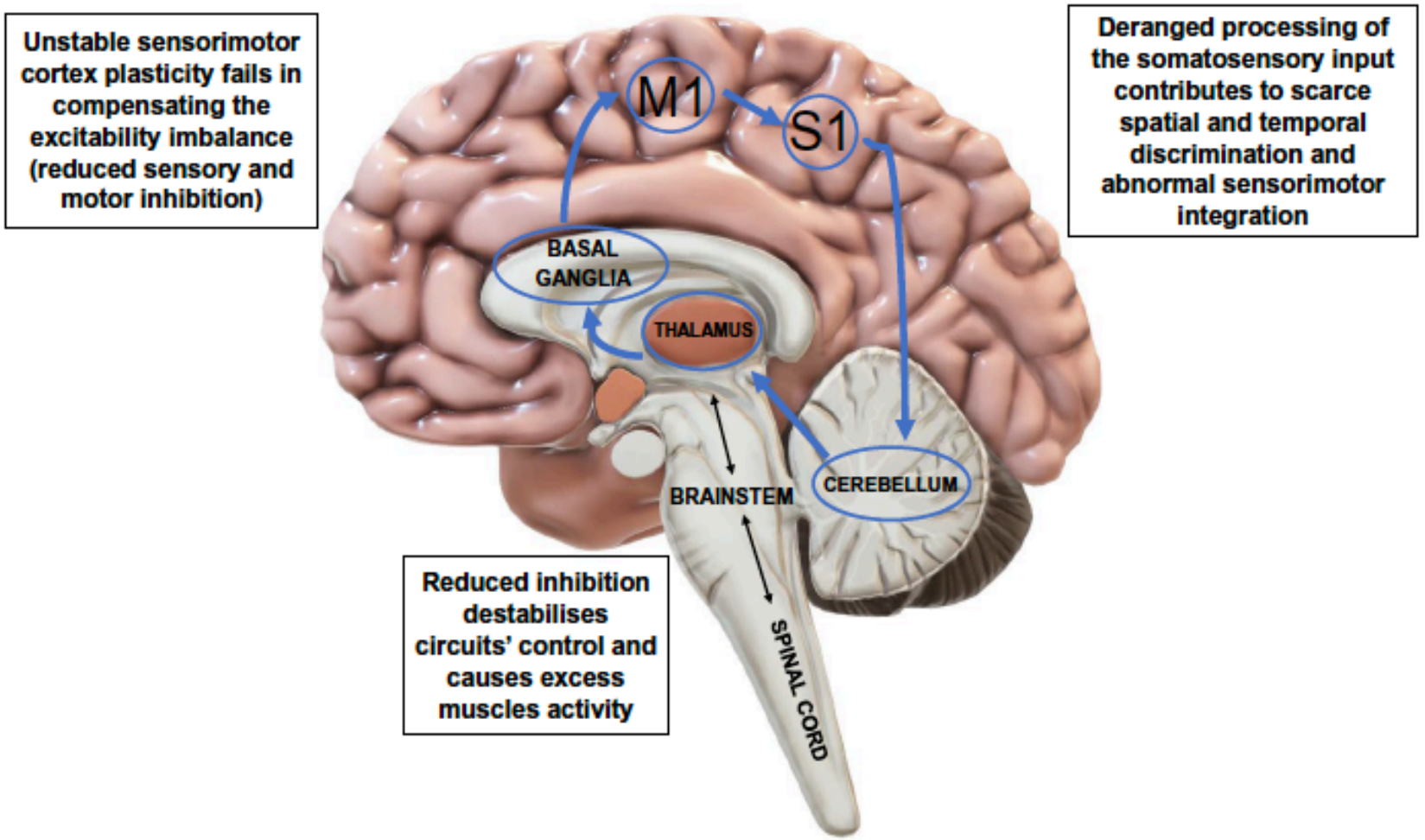

Definizione e fenomenologia della distonia

La distonia è un disturbo del movimento caratterizzato da contrazioni muscolari sostenute o intermittenti che causano movimenti ripetitivi, posture anormale, o entrambi.
I movimenti distonici sono tipicamente «patterned», talvolta con caratteristiche di torsione, può esservi associato il tremore.
La distonia è spesso elicitata o peggiorata dal movimento volontario ed associata ad un «overflow» della attivazione muscolare.

FONDAZIONE I.R.C.C.S. ISTITUTO NEUROLOGICO CARLO BESTA

Jinnah and Albanese, 2014

Classificazione della distonia
Asse I- Caratteristiche cliniche

01

- **Infantile** (0-2 anni)
- **Pediatrica** (3–12 anni)
- **Adolescenziale** (13–20 anni)
- **Giovane età adulta** (21–40 anni)
- **Tarda età adulta** (40 years and older)

03

- **Decorso clinico**– statica
  – progressiva
- **Variabilità a breve termine** – persistente
  – azione specifica
  – diurna
  – parossistica

- **Focale**
- **Segmentale**
- **Multifocale**
- **Emidistonia**
- **Generalizzata**

02

- **Isolata** (con o senza tremore)
- **Combinata** (con altre condizioni sitemiche o neurologiche)

04

Classificazione della distonia
Asse II- Classificazione eziologica

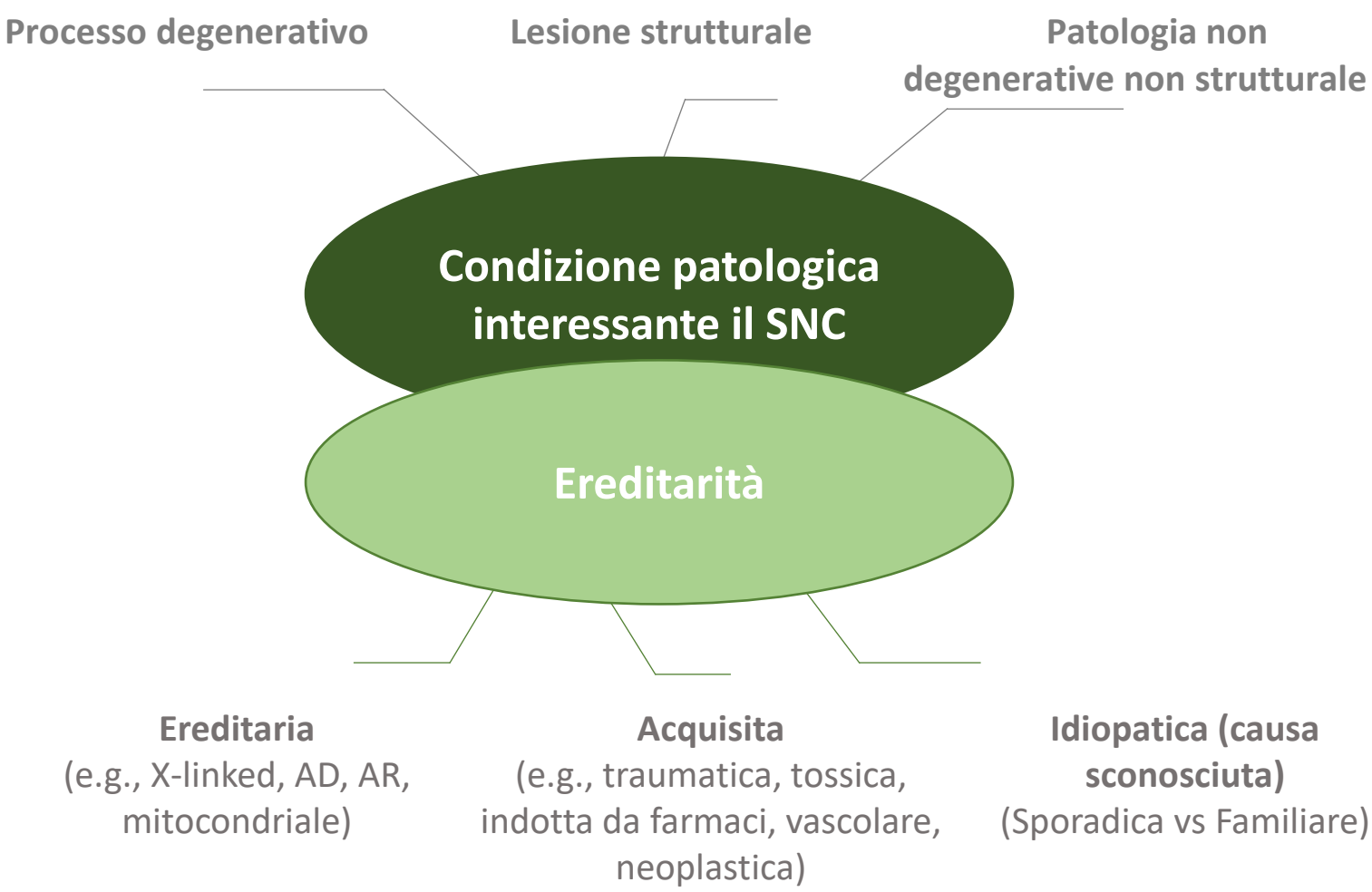

Primary (Isolated) dystonia. DYT1

Generalized Dystonia- Dystonic movements, postures, overflow

Gait Dystonia-Onset

Generalized Dystonia Primary (Isolated) Dystonia. DYT6. Dystonic movements and postures
Involvement of cranio-cervical muscles. Dystonic tremor

FONDAZIONE I.R.C.C.S.
ISTITUTO
NEUROLOGICO
CARLO
BESTA

Writing Dystonia



Hemidystonia



Distonia - Polimiografia

Pattern polimiografici della distonia:

- **Spasmi tonici**, quasi continui, della durata di diversi secondi che terminano con brevi periodi di silenzio elettrico
- **Burst mioclonici** di durata >50 ms e < 500 ms
- **Pattern oscillatorio**

Questi tre pattern possono essere presenti singolarmente o associati tra loro.

Distonia - Polimiografia

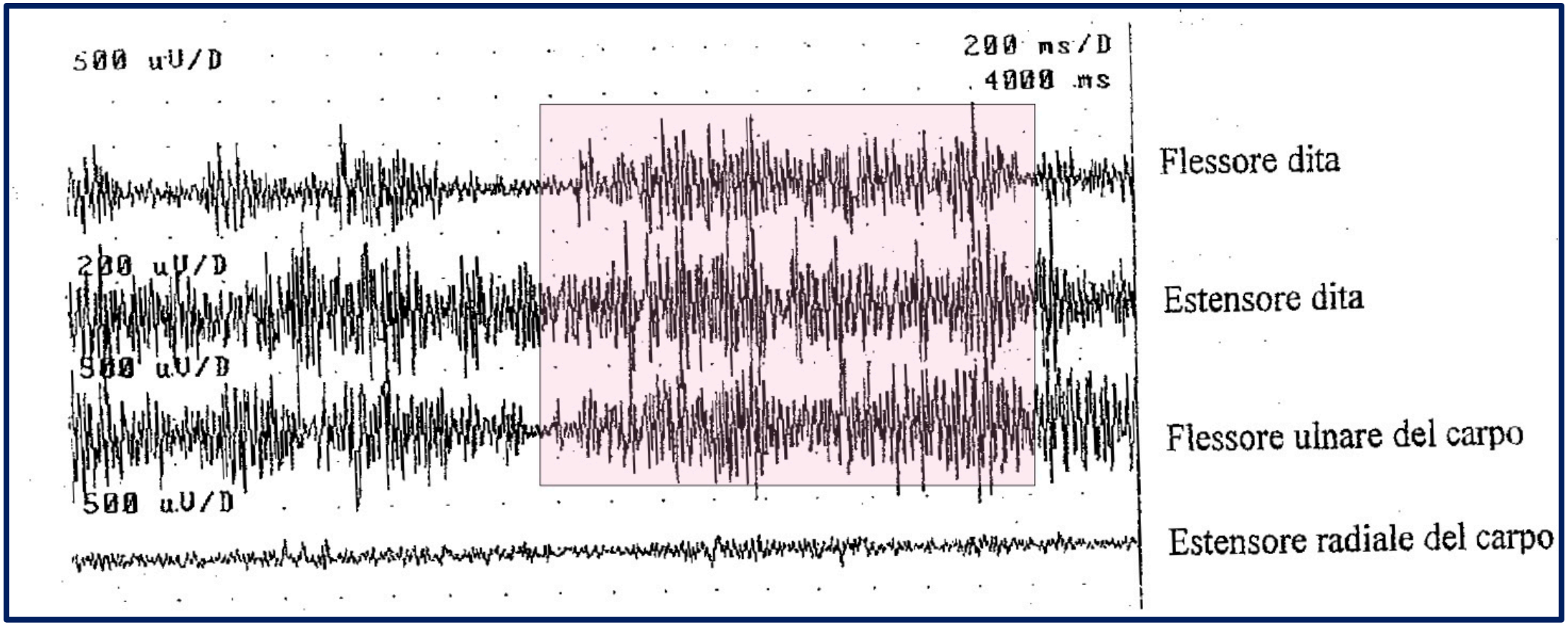

MANTENIMENTO POSTURALE PROTRATTO: attività tonica prolungata prevalente ai muscoli flessori, sincrona su antagonisti

Distonia - Polimiografia

- CO-CONTRAZIONE

L'attività muscolare non rispetta il principio di inibizione reciproca muscoli agonisti e antagonisti sono attivati in modo sincrono ai muscoli antagonisti.

- OVERFLOW

La contrazione muscolare si diffonde a muscoli che non sono coinvolti nello specifico atto motorio.

Si osservano a volte dei gesti antagonisti ("trucchi sensoriali", tattili o propriocettivi) che riducono la contrazione muscolare patologica.

Combined Dystonia. Myoclonus Dystonia DYT11
Progression of the disease

FONDAZIONE I.R.C.C.S. ISTITUTO NEUROLOGICO CARLO BESTA

Combined Dystonia.
Myoclonus Distonia DYT11 negative



Combined Dystonia.
Myoclonus Dystonia

FONDAZIONE I.R.C.C.S.
ISTITUTO
NEUROLOGICO
CARLO
BESTA

Movement Disorders
Vol. 23, No. 1, 2008, pp. 28–34
© 2007 Movement Disorder Society

FONDAZIONE I.R.C.C.S. ISTITUTO NEUROLOGICO CARLO BESTA

Myoclonus–Dystonia Syndrome: Clinical Presentation, Disease Course, and Genetic Features in 11 Families

Nardo Nardocci, MD,[1] Giovanna Zorzi, MD,[1] Chiara Barzaghi, MSc,[2] Federica Zibordi, MD,[1] Claudia Ciano, MD,[3] Daniele Ghezzi, MSc,[2] and Barbara Garavaglia, PhD[2]

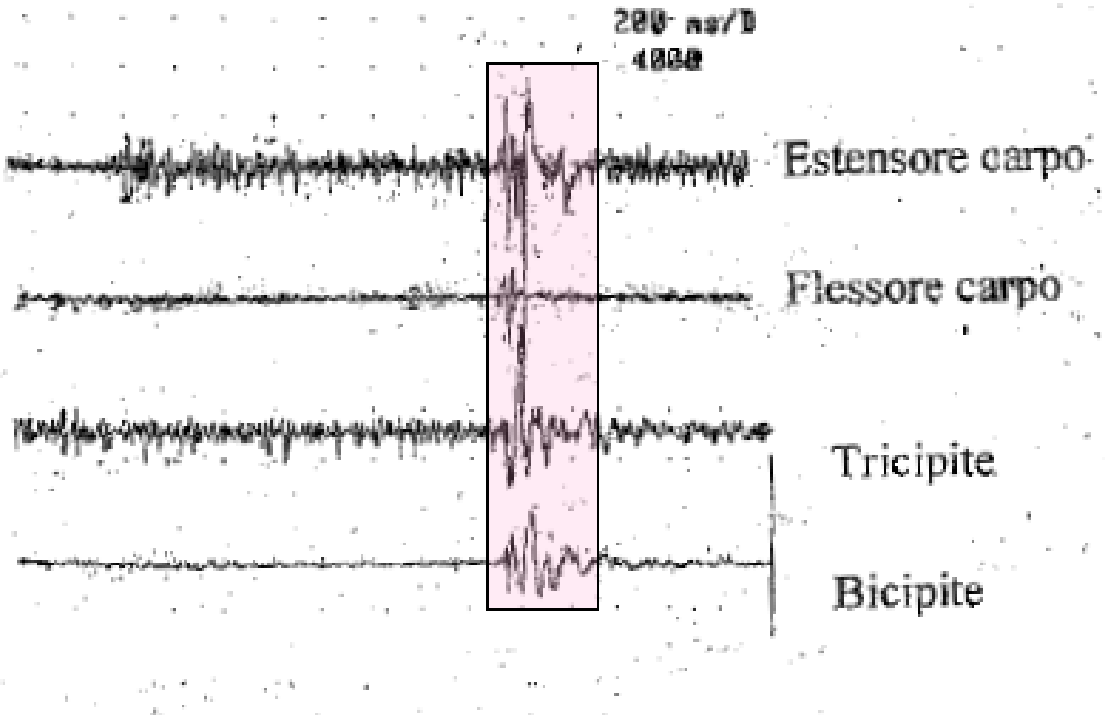

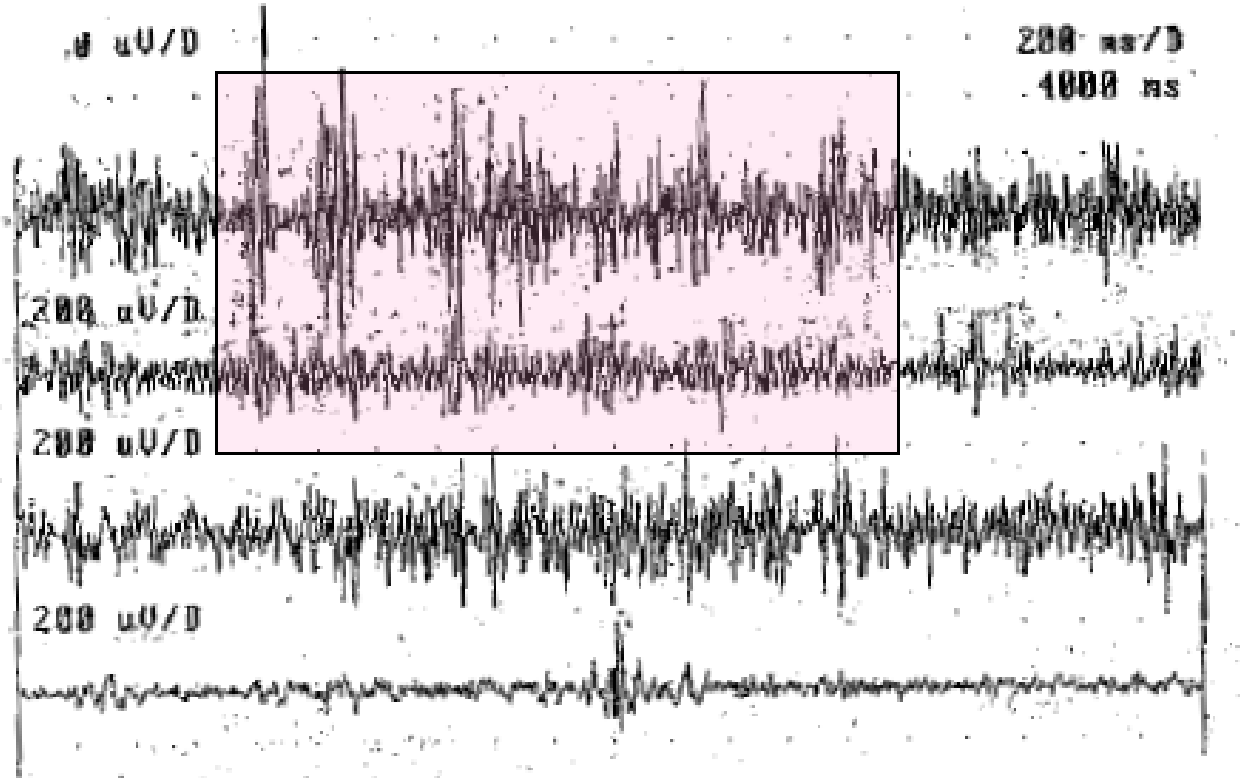

A riposo: sporadici burst di attività clonica 150-300 msec sincrona su antagonisti

Durante scrittura: attività tonica muscoli distali e tricipite Con sovraimposte bouffee di ampio voltaggio

A riposo

A riposo

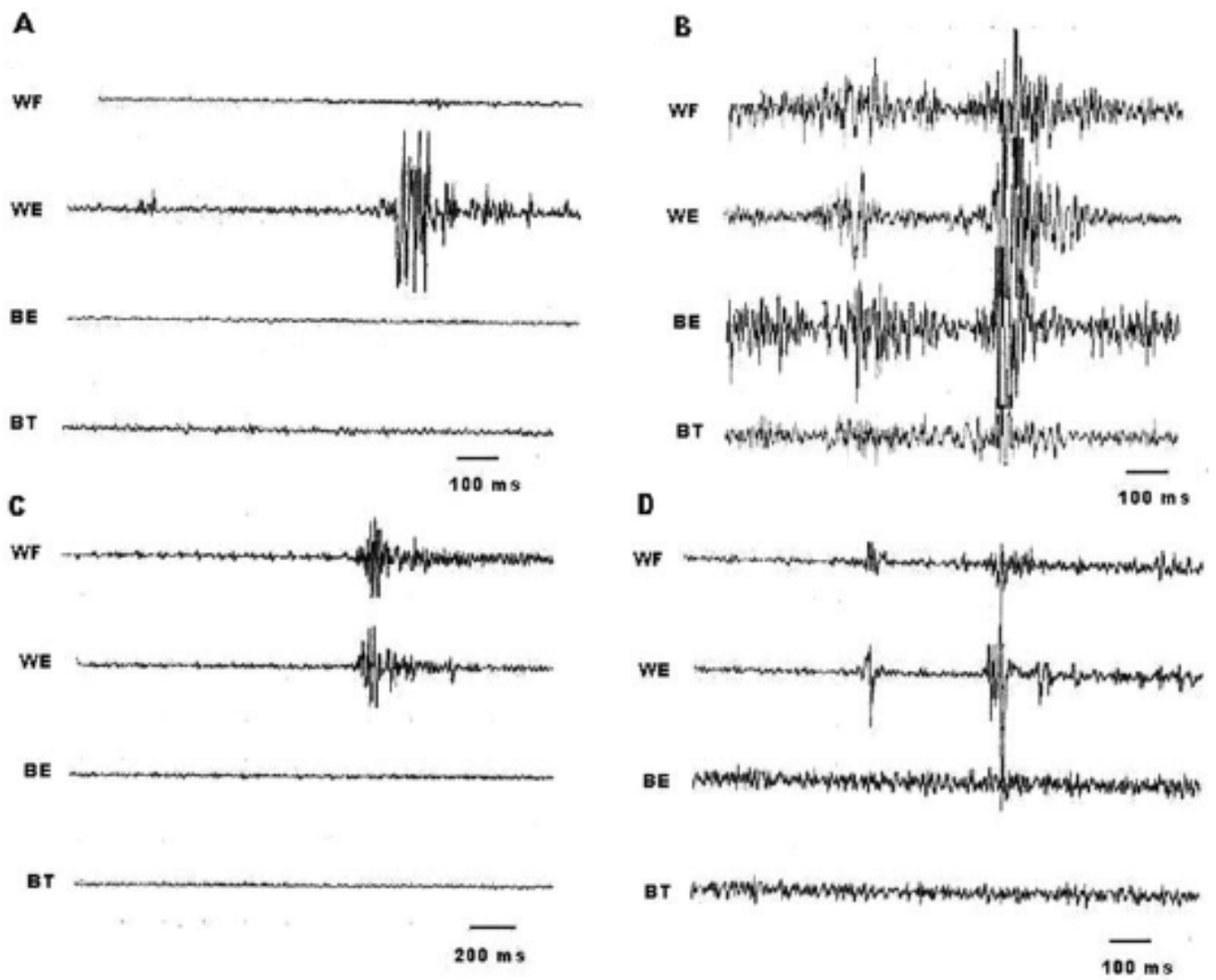

FIG. 2. EMG activity from Patient 4 (A, C, and D) and Patient 10 recorded with surface electrodes from upper right limb. Muscles are from top downwards: wrist flexors (WF), wrist extensors (WE), brachial biceps (BB) brachial triceps (BT). **A:** at rest on distal muscles isolated burst lasting 150 ms. **B:** prolonged tonic activity with superimposed repetitive EMG bursts lasting 200–400 ms during voluntary movements. **C:** synchronous bursts lasting 300 ms at rest on distal muscles. **D.** brief bursts (60–80 ms) on distal muscles during postural maintenance.

Movimento volontario

Mantenimento postura

Movement Disorders
Vol. 23, No. 1, 2008, pp. 28–34
© 2007 Movement Disorder Society

Myoclonus–Dystonia Syndrome: Clinical Presentation, Disease Course, and Genetic Features in 11 Families

Nardo Nardocci, MD,[1] Giovanna Zorzi, MD,[1] Chiara Barzaghi, MSc,[2] Federica Zibordi, MD,[1] Claudia Ciano, MD,[3] Daniele Ghezzi, MSc,[2] and Barbara Garavaglia, PhD[2]

ELSEVIER
Official Journal of the European Paediatric Neurology Society

Original article

Polymyography in the diagnosis of childhood onset movement disorders

C. Canavese[a], C. Ciano[b], G. Zorzi[a], F. Zibordi[a], C. Costa[a], N. Nardocci[a,*]

[a]UO Neuropsichiatria Infantile, Fondazione I.R.C.C.S. Istituto Neurologico Carlo Besta, Milano, Italy
[b]UO Neurofisiologia Clinica, Fondazione I.R.C.C.S. Istituto Neurologico Carlo Besta, Milano, Italy

3.3. Clinical–polymyographic comparison

Polymyographic features were compared with clinical classification in order to evaluate the role of polymyography in the identification of MD:

I. *Patients in which polymyography confirmed the clinically classified MD*
25 patients: five dystonia, four myoclonic-dystonia, five subcortical myoclonus, ten tremors and one dystonia+tremor.

II. *Patients in which polymyography disclosed an associated MD not clinically evident*
12 patients: subcortical myoclonus in seven patients with dystonia, tremor in three patients with dystonia, dystonia in two patients with myoclonus.

III. *Patients in which polymyography permitted to characterize the clinically unclassified MD (isolated or associated to a definite MD)*
17 patients: five myoclonic dystonia (one of them with associated ataxia), six subcortical myoclonus (four associated with dystonia and one associated with ataxia), four tremor and two subcortical myoclonus+tremor.

IV. *Others*
Seven patients clinically defined as having dystonia (isolated in one, associated with myoclonus in four or with unclassified MD in two): polymyographic findings of subcortical myoclonus in six, normal in one.

Distonia – Polimiografia: limiti

- **Limite nella collaborazione** o esecuzione di un atto motorio che coinvolga un singolo distretto: co-contrazione e overflow per difficoltà a limitare l'atto motorio ad una sola coppia di muscoli agonisti-antagonisti.

- Studi polimiografici in bambini con distonie geneticamente determinate possono non evidenziare chiari fenomeni di co-contrazione (**registrazione di superficie talora inefficace** per la valutazione di gruppi muscolari più profondi).

- La polimiografia non permette di chiarire l'eziologia della distonia

  anche la distonia di origine funzionale può mostrare la co-contrazione e l'overflow

  Non ci sono aspetti polimiografici distintivi della distonia funzionale.

Functional MD
Myoclonus-Dystonia phenotype

Functional movement disorders

Total patients with functional movement disorders (FMD): **37/136 (21%)**

F: 25 (68%)
M: 12 (32%)

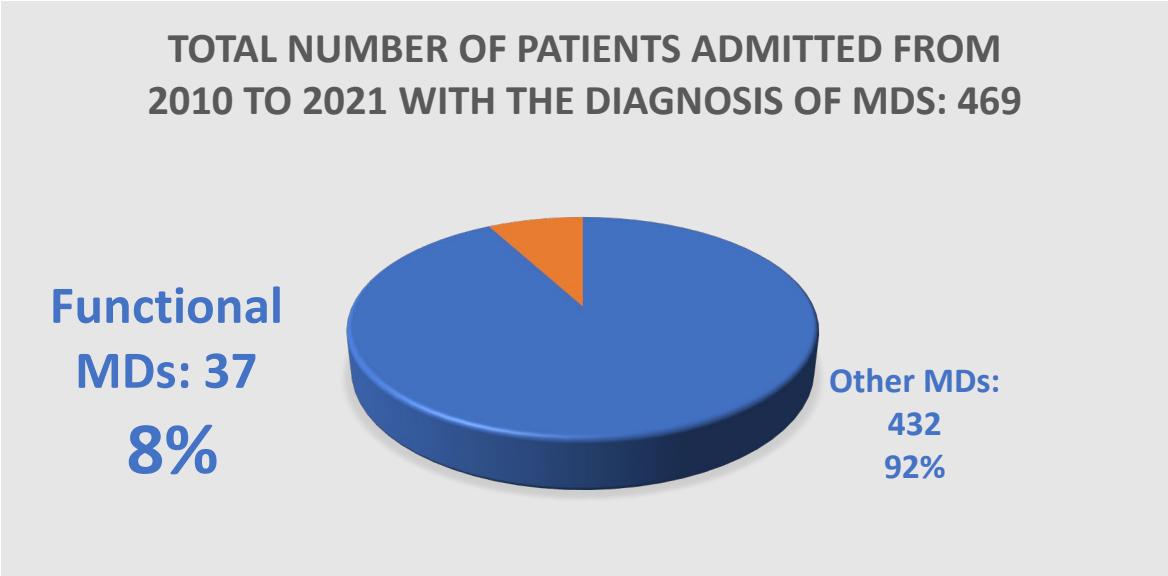

Incidence of Functional movement disorders among total diagnoses of functional neurological disorders

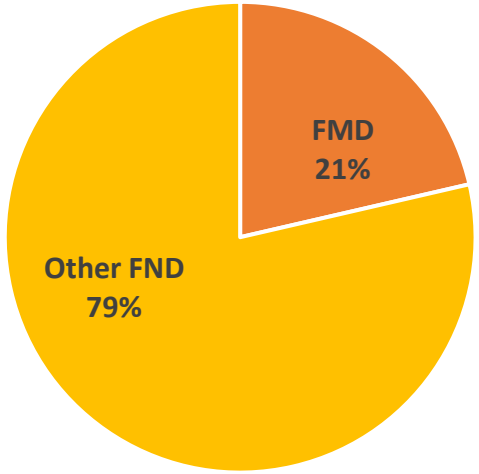

	Sex	Age of onset (years)	Age at admission (years)	Temporal latency between onset and hospitalization (years)
Mean	F	13.8	15.1	1.37
	M	11.5	12.8	1.31
Median	F	14.0	15.6	0.800
	M	12.5	12.9	0.800
Standard deviation	F	2.60	2.10	1.60
	M	3.48	3.11	1.50
Minimum	F	7.00	9.50	0.00
	M	5.00	6.90	0.00
Maximum	F	18.0	18.3	6.20
	M	16.0	16.8	5.00

Functional movement disorders

Total patients with functional movement disorders (FMD): **37 (21%)**

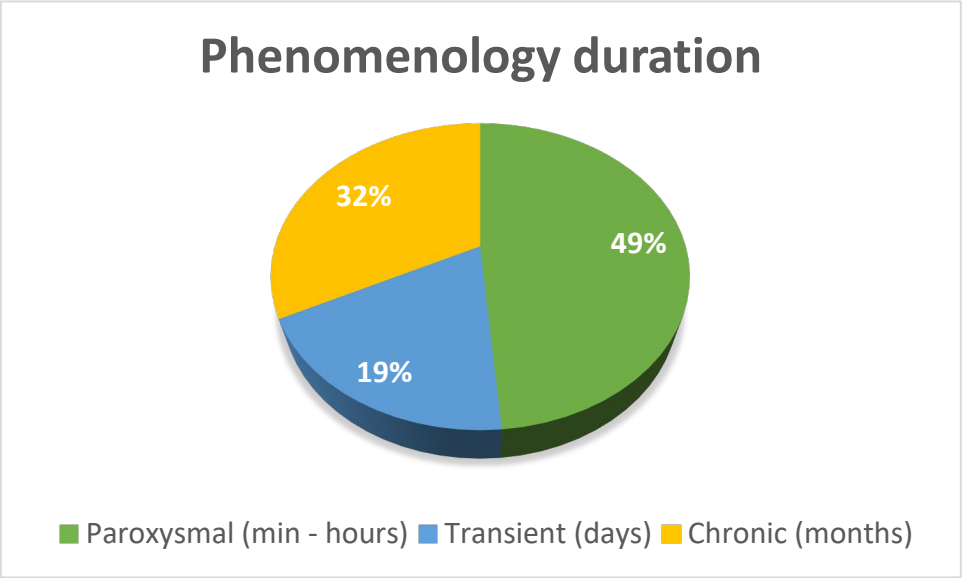

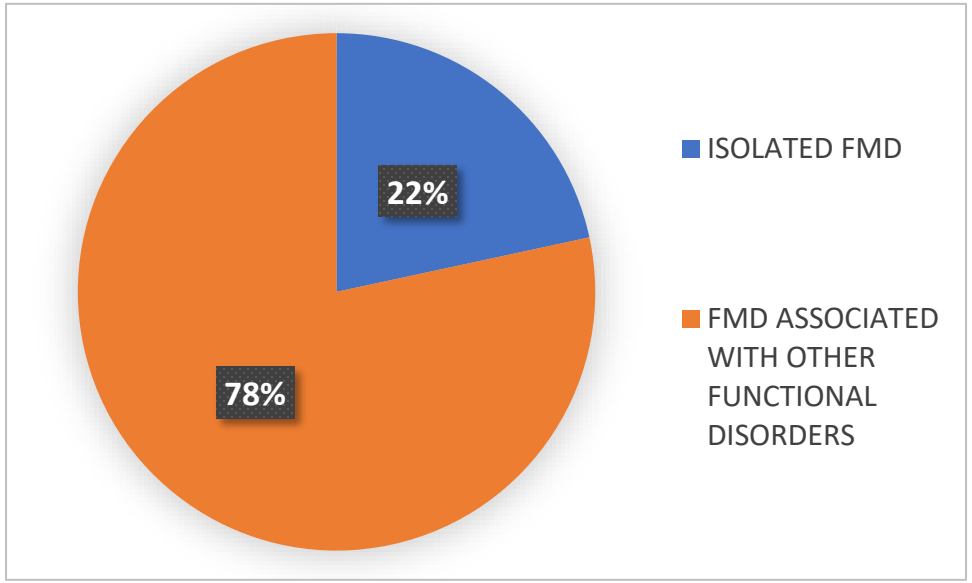

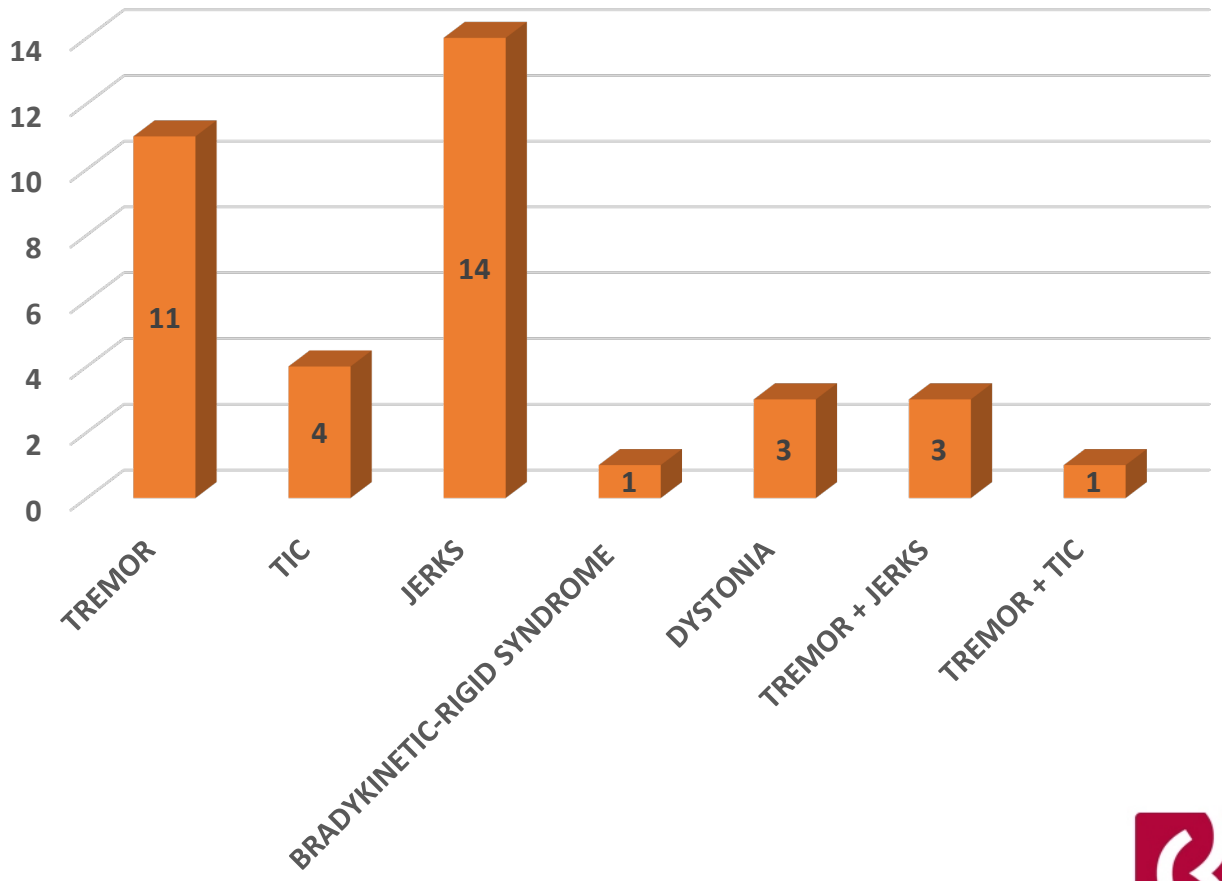

Functional movement disorders

Total patients with functional movement disorders (FMD): **37 (21%)**

VIDEO-POLIGRAPHY

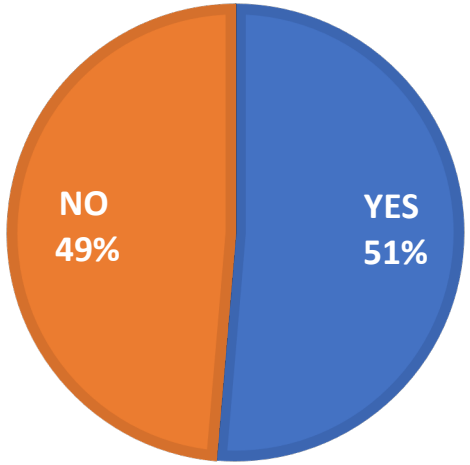

Total number of video-poligraphies: 19

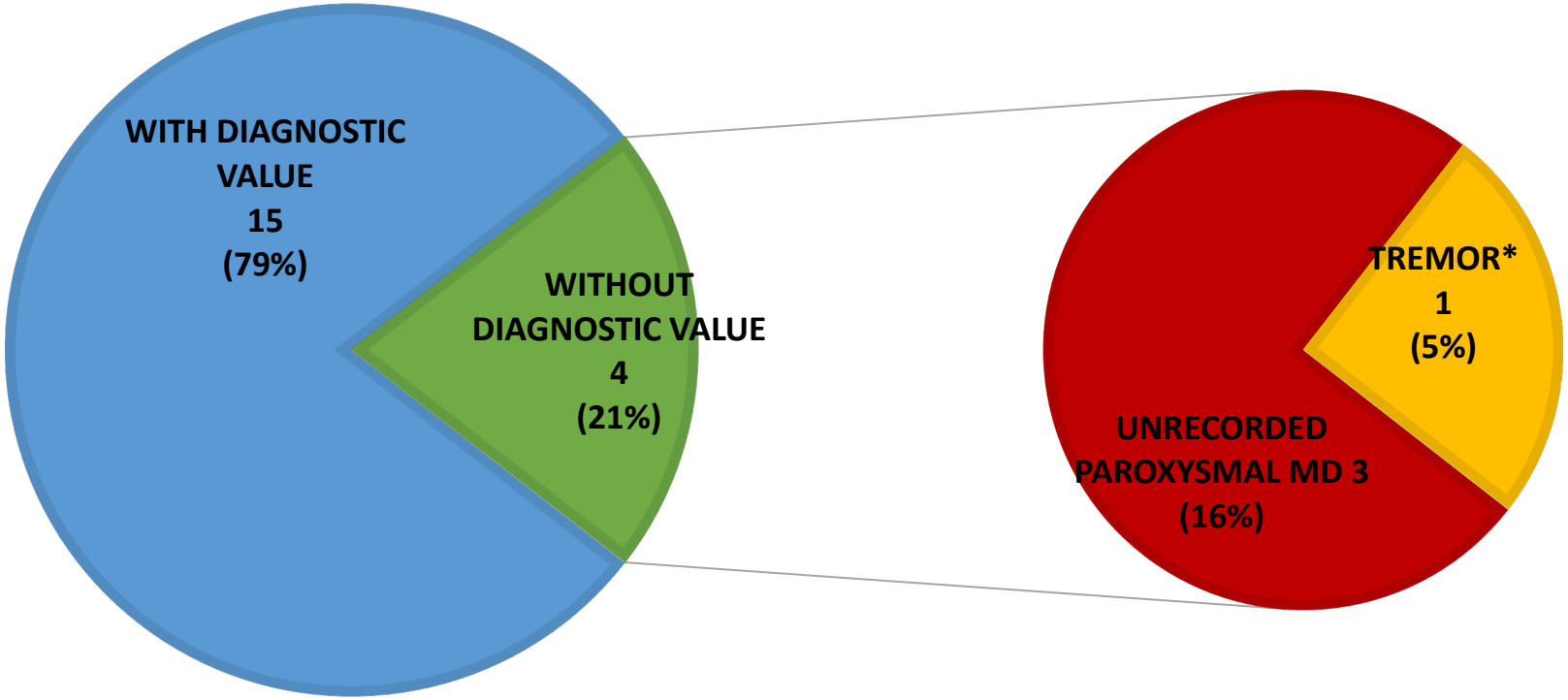

*8-9 Hz regular tremor, without features of functional tremor.

FONDAZIONE I.R.C.C.S. ISTITUTO NEUROLOGICO CARLO BESTA

Contents lists available at ScienceDirect

Clinical Neurophysiology

journal homepage: www.elsevier.com/locate/clinph

Somatosensory Evoked Potentials and Central Motor Conduction Times in children with dystonia and their correlation with outcomes from Deep Brain Stimulation of the Globus pallidus internus

Verity M. McClelland [a,b], Doreen Fialho [c], Denise Flexney-Briscoe [c], Graham E. Holder [c,d,e], Markus C. Elze [f], Hortensia Gimeno [b,g], Ata Siddiqui [h,i], Kerry Mills [a], Richard Selway [j], Jean-Pierre Lin [b,*]

Results: Abnormal CMCTs and SEPs were found in 19% and 47% of children respectively and were observed more frequently in secondary than primary dystonia. Of children proceeding to DBS, better outcome was seen in those with normal ($n = 78/89$) versus abnormal CMCT ($n = 11/89$) ($p = 0.002$) and those with normal ($n = 35/51$) versus abnormal SEPs ($n = 16/51$) ($p = 0.001$). These relationships were independent of dystonia aetiology and cranial MRI findings.

Conclusions: CMCTs and SEPs provide objective evidence of motor and sensory pathway dysfunction in children with dystonia and relate to DBS outcome.

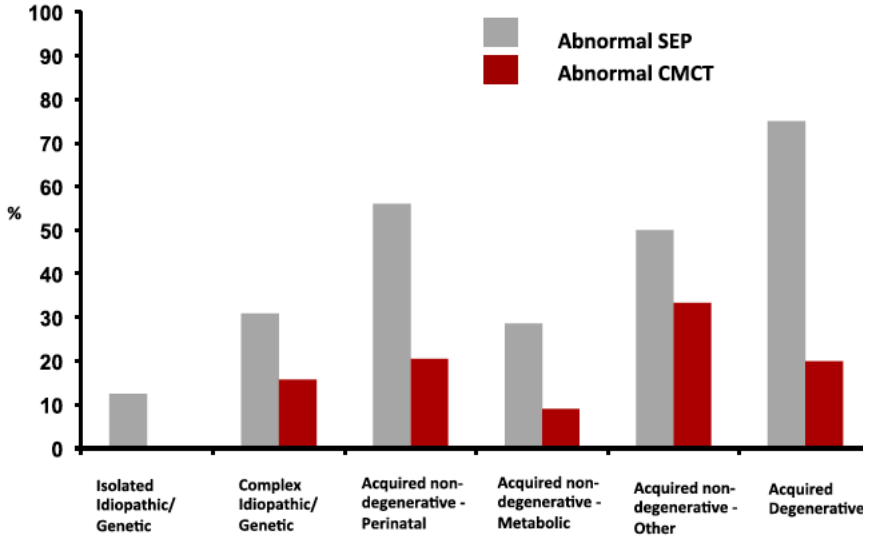

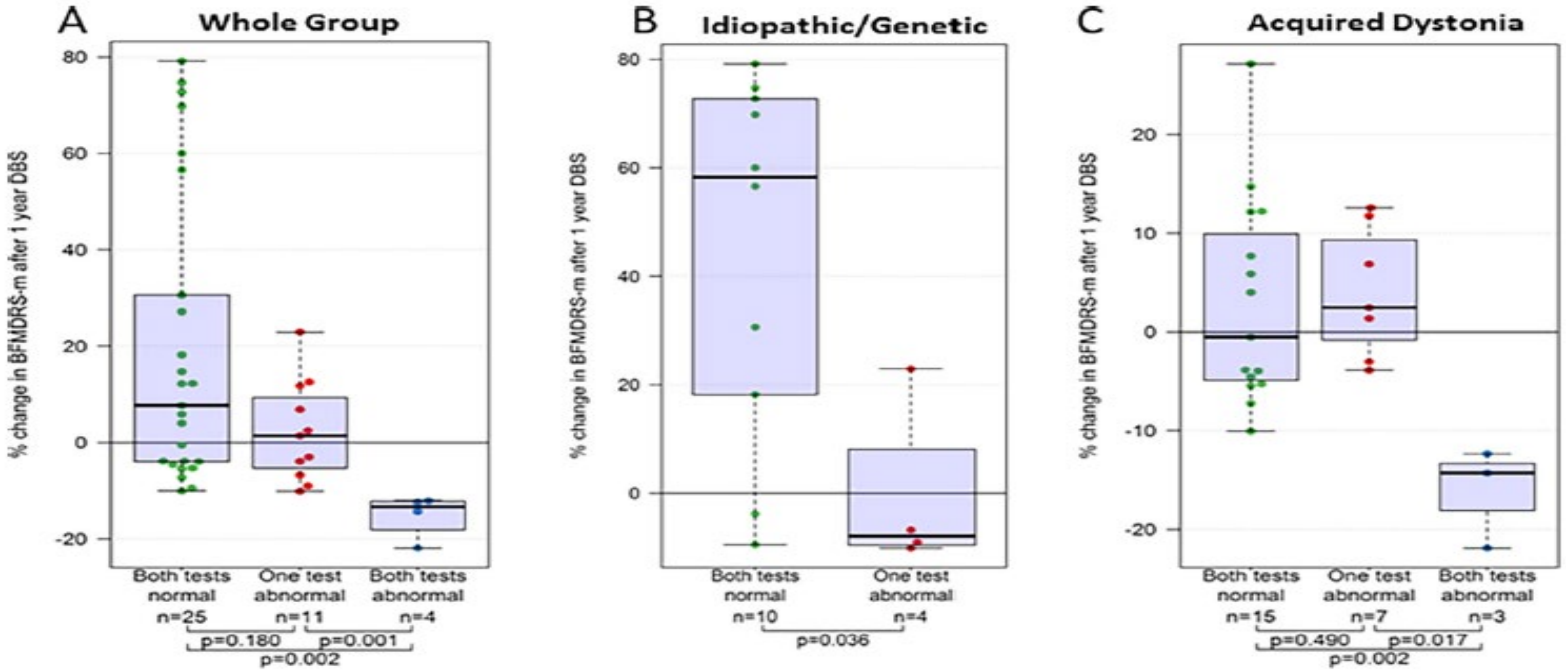

FONDAZIONE I.R.C.C.S. ISTITUTO NEUROLOGICO CARLO BESTA

The neurophysiology of paediatric movement disorders

Verity M. McClelland[a,b,c]

Curr Opin Pediatr 2017, 29:683–690

KEY POINTS

- The neurophysiology of paediatric movement disorders is an under-researched area, with most studies focusing on hemiplegic cerebral palsy and few on other conditions.
- Neurophysiological studies have provided significant insights into the pathophysiology of movement disorders.
- TMS has been used to demonstrate changes in corticospinal connectivity and excitability in movement disorders and evidence of neuroplasticity in the developing or injured brain.
- Evoked potentials and event-related changes in spectral EEG activity have provided evidence of abnormal sensory processing/sensorimotor integration in a range of paediatric movement disorders.
- Neurophysiological tools provide objective evidence of nervous system function and have great potential for use as biomarkers and/or for biofeedback as technologies develop.

Table 2. Complementarity of imaging and neurophysiology techniques

Neurophysiology **TMS, EEG, MEG, EMG**	**Imaging** **MRI, fMRI, DTI, PET**
Provide information on nervous system function	Provide information on nervous system structure (MRI and DTI) or function (fMRI and PET)
Record brain activity (EEG) or muscle activity (EMG) directly	Assesses function via changes in blood flow (fMRI) or metabolic activity (PET) in relation to brain activity.
No requirement for sedation or general anaesthetic	Sedation or general anaesthetic often needed in children with movement disorders to avoid contamination by movement artefact
No radioactivity	PET requires injection of radioactive tracer
Relatively inexpensive	Expensive scanning time
Acquisition time less of a problem	Scan time limited by cost and requirement for sedation
TMS activates predominantly the fastest conducting corticospinal tract fibres	DTI not limited to fastest conducting corticospinal tract fibres
Temporal resolution very good (ms)	Temporal resolution less good (s– min)
EEG spatial resolution less good (can be better with MEG)	Spatial resolution very good
Cerebellum and deep structures not easily accessible	Imaging can provide good information about posterior fossa and deep structures
EEG data are recorded in real-time and ambulatory recording is feasible, making neurophysiological signals ideal candidates for biofeedback in closed-loop neuromodulation systems	Data are acquired at a specific time-point, providing a snap-shot of brain structure or transient measure of function

Both imaging and neurophysiology techniques have advantages and disadvantages, including those listed here. A multimodal assessment is therefore ideal. DTI, diffusion tensor imaging; EEG, electroencephalogaphy; EMG, electromyography; fMRI, functional MRI; MEG, magnetoencephlogrpahy; TMS, transcranial magnetic stimulation.



DIPARTIMENTO NEUROSCIENZE PEDIATRICHE



FONDAZIONE I.R.C.C.S.
ISTITUTO NEUROLOGICO
CARLO BESTA

Laura Canafoglia

SS Diagnostica epilettologica integrata
UOC Neurologia 7

Paola Lanteri
Claudia Ciano
Mikael Gianandrea Izzo

Neurofisiopatologia
UOC Neurologia 6

FONDAZIONE I.R.C.C.S. ISTITUTO NEUROLOGICO CARLO BESTA